Chapter 13b – THYROTROPIN-SECRETING PITUITARY ADENOMAS

Paolo Beck-Peccoz, M.D., Professor of Endocrinology
University of Milan, Pad. Granelli, Via F. Sforza 35, 20122-Milan, Italy paolo.beckpeccoz@unimi.it>

Luca Persani, M.D., Ph.D., Associated Professor of Endocrinology
University of Milan, Via Zucchi 18 – 20095 Cusano, Milan, Italy

<luca.persani@unimi.it>

Updated 01 Jan 2013

INTRODUCTION

The thyrotropin (TSH)-secreting pituitary adenomas (TSH-omas) are a rare cause of hyperthyroidism. In this situation, TSH secretion is autonomous and refractory to the negative feedback of thyroid hormones (inappropriate TSH secretion) and TSH itself is responsible for the hyperstimulation of the thyroid gland and the consequent hypersecretion of T4 and T3 (1,2). Therefore, this entity can be appropriately classified as a form of "central hyperthyroidism". The first case of TSH-oma was documented in 1960 by measuring serum TSH levels with a bioassay (3).
In 1970, Hamilton et al. (4) reported the first case of TSH-oma proved by measuring TSH by RIA. Classically, TSH-omas were diagnosed at the stage of invasive macroadenoma and were considered difficult to cure. However, the advent of ultrasensitive immunometric assays, routinely performed as first line test of thyroid function, has greatly improved the diagnostic workup of hyperthyroid patients, allowing the recognition of the cases with unsuppressed TSH secretion. As a consequence, TSH-omas are now more often diagnosed earlier, before the stage of macroadenoma, and an increased number of patients with normal or elevated TSH levels in the presence of high free thyroid hormone concentrations have been recognized. Signs and symptoms of hyperthyroidism along with values of thyroid function tests similar to those found in TSH-oma may be recorded also among patients affected with resistance to thyroid hormones (RTH) (5-7). This form of RTH is called pituitary RTH (PRTH), as the resistance to thyroid hormone action appears more severe at the pituitary than at the peripheral tissue level. The clinical importance of these rare entities is based on the diagnostic and therapeutic challenges they present. Failure to recognize these different diseases may result in dramatic consequences, such as improper thyroid ablation in patients with central hyperthyroidism or unnecessary pituitary surgery in those with RTH. Conversely, early diagnosis and correct treatment of TSH-omas may prevent the occurrence of neurological and endocrinological complications, such as visual defects by compression of the optic chiasm, headache and hypopituitarism, and should improve the rate of cure.

EPIDEMIOLOGY

Up to date, about 450 cases of TSH-oma have been published (1, 2, 8-61). The prevalence of these adenomas is about one case per million, and they account for about 0.5%-2.8% of all pituitary adenomas whose prevalence in the general population is about 0.03%. However, this figure is probably underestimated as the number of reported cases of TSH-omas tripled in the last decade. Recent data from European northern countries show a national incidence of TSH-omas ranging from 0.15 to 0.3/million (53, 61). The increased number of reported cases principally results from the introduction of ultrasensitive TSH immunometric assays and from improved practioner awareness. Based on the finding of measurable serum TSH levels in the presence of elevated FT4 and FT3 concentrations, many patients previously thought to be affected with primary hyperthyroidism (Graves' disease), can nowadays be correctly diagnosed as patients with TSH-oma or, alternatively, with RTH (1, 2, 5-7).

The presence of a TSH-oma has been reported at ages ranging from 8 to 84 years (2, 58, 59). However, most patients are diagnosed around the fifth-sixth decade of life. TSH-omas occur with equal frequency in men and women, in contrast with the female predominance seen in other more common thyroid disorders. Familial cases of TSH-oma have been reported as part of multiple endocrine neoplasia type 1 syndrome (MEN 1) (10) and in familial isolated pituitary adenoma (FIPA) family with AIP mutation (52).

PATHOLOGICAL ASPECTS

Immunostaining studies showed the presence of TSH beta subunit, either free or combined, in all adenomatous cells from every type of TSH-oma, with only few exceptions (1, 2, 8, 9, 62). The majority of TSH-secreting adenomas (72%) are secreting TSH alone, often accompanied by unbalanced hypersecretion of α-subunit of glycoprotein hormones (α-GSU) (Table 1).

Table 1. Recorded cases of TSH-secreting adenomas of different type (updated end December 2012).

	Number	% of total
Total TSH-secreting adenomas (TSH-omas)	442	---
Pure TSH-omas	310	70.1
TSH-omas with associated hypersecretion (mixed TSH-omas)	132	29.9
Mixed TSH/GH-omas	79	17.9
Mixed TSH/PRL-omas	45	10.2
Mixed TSH/FSH/LH-omas	8	1.8

Interestingly, the existence of TSH-omas composed of two different cell types, one secreting α-GSU alone and another cosecreting α-GSU and the entire TSH molecules (mixed TSH/α-GSU adenomas), was documented by using double gold particle immunostaining (63). The presence of a mixed TSH/α-GSU adenoma is suggested by the finding of an extremely high α-GSU/TSH molar ratio and/or by the observation of dissociated TSH and α-GSU responses to TRH (1). Classic mixed adenomas characterized by concomitant hypersecretion of other anterior pituitary hormones are found in about 30% of patients. Hypersecretion of GH and/or PRL, resulting in acromegaly and/or amenorrhea/galactorrhea syndrome, are the most frequent association. This may be due to the fact that somatotroph and lactotroph cells share with thyrotropes common transcription factors, such as Prop-1 and Pit-1. Rare is the occurrence of mixed TSH/gonadotropin adenoma, while no association with ACTH hypersecretion has been documented to date probably due to the distant origin of corticotroph and thyrotroph lineages. Nonetheless, a positive immunohistochemistry for one or more pituitary hormone does not necessarily correlates with its or their hypersecretion in vivo (9, 62). Accordingly, clinically and biochemically silent thyrotropinomas have been reported (9, 64, 65). Moreover, true TSH-secreting tumors associated with Hashimoto's thyroiditis and hypothyroidism have been documented (1, 39, 66, 67).
Microadenomas, with a diameter <1 cm, were recorded in less than 15% of the cases before 1996 (22), but their prevalence among the total TSH-oma is progressively increasing due to improved testing of thyroid function and awareness among Endocrinologists and General Practitioners. In the series of 13 TSH-oma newly diagnosed at our department after 1996 only 5 were at the stage of macroadenomas. As a matter of fact, most TSH-omas had been diagnosed at the stage of macroadenomas and showed localized or diffuse invasiveness into the surrounding structures, especially into the dura mater and bone (1, 8, 9, 15, 22, 62). Extrasellar extension in the supra- and/or parasellar direction were present in the majority of cases. The occurrence of invasive macroadenomas is particularly high among patients with previous thyroid ablation by surgery or radioiodine (Figure 1) (1, 2). This finding brings to evidence the

deleterious effects of incorrect diagnosis and treatment of these adenomas, and the relevant action on tumor growth exerted by the reduction of circulating thyroid hormone levels through an altered feedback mechanism. Such an aggressive transformation of the tumor resembles that occurring in Nelson's syndrome after adrenalectomy for Cushing's disease. Finally, recent data suggest that somatic mutations of thyroid hormone receptor beta may be responsible for the defect in negative regulation of TSH secretion in some TSH-omas (56, 68, 69). In addition, alteration in iodothyronine deiodinase enziyme expression and function may contribute to the resistance of tumor cells to the feedback mechanism of elevated thyroid hormone levels (70). However, these data were not confirmed by another study on this topic (71).

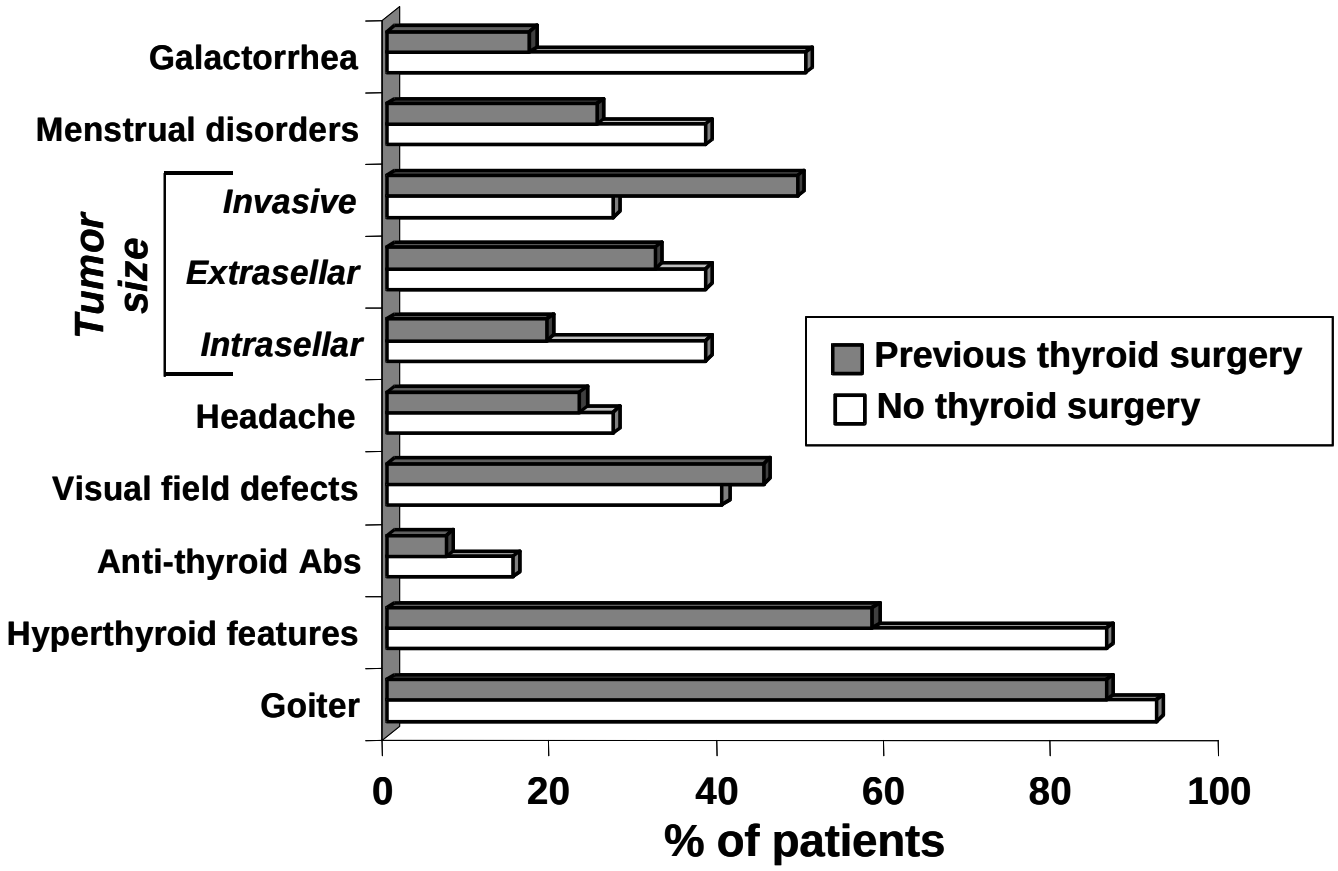

Figure 1. Clinical manifestations in patients with TSH-secreting adenomas. Patients have been divided into two categories according to previous thyroid surgery. The presence of goiter is the rule, even in patients with partial thyroidectomy. Hyperthyroid features may be overshadowed by those of associated hypersecretion/deficiency of other pituitary hormones. Invasive tumors are seen in about half of the patients with previous thyroidectomy and in 1/4 of untreated patients ($P<0.01$ by Fisher's exact test). Intrasellar tumors show an opposite distribution pattern.

The consistency of TSH-omas is usually very fibrous, and sometimes so hard that they deserve the name of "pituitary stone" (72). Increased basic fibroblast growth factor (bFGF) levels were found in blood from two patients with invasive mixed PRL/TSH-secreting adenomas characterized by marked fibrosis (73). The tumoral origin of bFGF was confirmed by the finding of specific transcript in the tissues removed at surgery, suggesting a possible autocrine role for this growth factor in tumor development. By light microscopy and appropriate staining, adenoma cells usually have chromophobic appearance. Cells are often arranged in cords, they frequently appear polymorphous and characterized by large nuclei and prominent nucleoli. Ultrastructurally, the well differentiated adenomatous thyrotrophs resemble the normal ones, while the poorly differentiated adenomas are composed of elongated angular cells with irregular nuclei, poorly developed RER, long cytoplasmic processes and sparse small secretory granules (50-200 nm) usually lining up along the cell membrane (9, 62). Generally, no exocytosis is detectable. Cells with abnormal morphology or mitoses are occasionally found which may be mistaken for a pituitary malignancy or metastases from distant carcinomas (74). Nevertheless, the transformation of a TSH-oma into a pituitary carcinoma with multiple metastases has been seldom reported (35, 60, 75). Future malignant behaviour might be predicted by the finding of very high circulating levels of free α-subunit, whereas a concomitant, spontaneous and marked decrease of both TSH and α-GSU serum concentrations might indicate that the tumor is becoming less differentiated and correlate with invasive and metastatic behavior. Finally, in a mouse model of TSH-oma, the activation of phosphatidylinositol 3-

kinase promotes aberrant pituitary growth that may induce trasformation of the adenoma into a carcinoma (76).

MOLECULAR AND IN VITRO SECRETION STUDIES

The molecular mechanisms leading to the formation of TSH-omas are presently unknown, as is true for the large majority of pituitary adenomas. X-chromosomal inactivation analysis demonstrated that most pituitary adenomas, including the small number of TSH-omas investigated, derive from the clonal expansion of a single initially transformed cell. Accordingly, the general principles of tumorigenesis, that assume the presence of a transforming event providing gain of proliferative function followed by secondary mutations or alterations favoring tumor progression, presumably also apply to TSH-omas.

A large number of candidate genes, including common proto-oncogenes and tumor suppressor genes as well as pituitary specific genes, have been screened for mutations able to confer growth advantage to thyrotrope cells. Although most information available so far concerns other more frequent pituitary adenomas, these approaches are now extending to TSH-omas. In analogy with the other pituitary adenomas, no mutations in oncogenes commonly activated in human cancer, particularly *Ras*, have been reported in TSH-omas. In contrast with GH-secreting adenomas in which the oncogene *gsp* is frequently present, none of the TSH-oma screened has been shown to express activating mutations of genes encoding for G protein subunits, such as αs, αq, α11 or αi2 (77). Similarly, no mutations in the TRH receptor or dopamine D2 receptor genes (77, 78) have been reported in 9 and 3 TSH-omas, respectively, while these tumors were not screened for the alterations in protein kinase C, previously identified in some invasive tumors. In consideration of the crucial role that the transcription factor Pit-1 exerts on cell differentiation and PRL, GH and TSH gene expression, Pit-1 gene has been screened for mutations in 14 TSH-omas and found to be wild-type (2). By contrast, as it occurs in GH-omas, Pit-1 was demonstrated to be overexpressed also in TSH-omas, although the proliferative potential of this finding remains to be elucidated (2, 62).

In addition to activating mutations or overexpression of protooncogenes, tumors may originate from the loss of genes with antiproliferative action. As far as the loss of anti-ncogenes is concerned, no loss of p53 was found in one TSH-oma studied, while the loss of retinoblastoma gene (Rb), which is however unaltered in other pituitary adenomas, was not investigated in TSH-omas. Another candidate gene is menin, the gene responsible for the multiple endocrine neoplasia type 1 (MEN1). In fact , 3-30% of sporadic pituitary adenomas show loss of heterozygosity (LOH) on 11q13, where menin is located, and LOH on this chromosome seems to be associated with the transition from the non-invasive to the invasive phenotype. A recent screening study carried out on 13 TSH-omas using polymorphic markers on 11q13 showed LOH in 3, but none of them showed a menin mutation after sequence analysis (79). Interestingly, hyperthyroidism due to TSH-omas has been reported in five cases within a familial setting of multiple endocrine neoplasia type 1 syndrome (1, 2, 10). In addition, LOH and particular polymorphisms at the somatostatin receptor type 5 gene locus seems to be associated with an aggressive phenotype and resistance to somatostatin analog treatment (80). Finally, germline mutations in the aryl hydrocarbon receptor interacting protein (AIP) are know to be involved in sporadic pituitary tumorigenesis, but no mutations were found in a single TSH-oma (52, 81).

The extreme refractoriness of neoplastic thyrotrophs to the inhibitory action of thyroid hormones indicates mutant forms of thyroid hormone receptors (TR) as for other potential candidate oncogenes. Absence of TRα1, TRα2 and TRβ1 expression was reported in one TSH-oma (82), but aberrant alternative splicing of thyroid hormone receptor β2 mRNA encoding TRβ variant lacking T3 binding activity and other TRβ mutations were recently shown as a mechanism for impaired T3-dependent negative regulation of both TSHβ and α-GSU in tumoral tissue (68, 69). Moreover, an aberrant expression of a novel thyroid hormone receptor β isoform (TRβ4) may partly contribute to the inappropriate secretion of TSH in TSH-omas (56). Several patients with TRbeta1 mutation and RTH phenotype have recently been described to bear pituitary lesions at imaging of the sella region, raising diagnostic and therapeutic dilemmas (30, 83, 84). The results of dynamic testing of TSH secretion were consistent with RTH, rather than TSH-omas, indicating that these lesions are likely to be pituitary incidentalomas, whose prevalence in nonselected autoptic series reaches 20%.

Pharmacological manipulations in short-term cultures of TSH-omas indicate that these tumors express a large number of functioning receptors. Although *in vivo* TSH response to TRH is usually absent, several in vitro studies showed either the presence or the absence of TSH response, indicating that the majority of tumors possess TRH receptor (2). Similarly, somatostatin (SRIH) binding experiments indicate that almost all TSH-omas express a variable number of SRIH receptors, the highest SRIH-binding site densities being found in mixed GH/TSH adenomas (57, 85). Since somatostatin analogs are highly effective in reducing TSH secretion by neoplastic thyrotrophs (12, 13, 85), the inhibitory pathway mediated by somatostatin receptors appears to be largely intact in such adenomas. Consistently, there is a good correlation between SRIH binding capacity and maximal biological response, as quantified by inhibition of TSH secretion and *in vivo* restoration of euthyroid state (57, 86-88). The presence of dopamine receptors in TSH-omas was the rationale for therapeutic trials with dopaminergic agonists, such as bromocriptine (57, 89). Several studies have shown a large heterogeneity of TSH responses to dopaminergic agents either in primary cultures or in vivo (1, 41, 90, 91). Effects of these two inhibitory agents should be nowadays re-evaluated in light of the demonstration of the possible heterodimerization of somatostatin receptor subtype 5 (sst5) and dopamine D2 receptor (92).

CLINICAL FINDINGS

Patients with TSH-oma present with signs and symptoms of hyperthyroidism that are frequently associated with those related to the pressure effects of the pituitary adenomas, causing loss of vision, visual field defects and/or loss of anterior pituitary function (Figure 1). TSH-omas may occur at any age and, in contrast with the common thyroid disorders, there is no preferential incidence in females (1, 8, 22). Due to the long history of thyroid dysfunction, many patients had been mistakenly diagnosed as having primary hyperthyroidism (Graves' disease), and about one third had inappropriate thyroid ablation by thyroidectomy and/or radioiodine. True coexistance of Graves' disease and TSH-oma has been reported in few cases (55). Clinical features of hyperthyroidism are usually present, sometimes milder than expected given the level of thyroid hormones, probably due to their longstanding duration. Consistently, several untreated patients with TSH-oma were described as clinically euthyroid (1, 59, 65). Moreover, hyperthyroid features can be overshadowed by those of acromegaly in the patients with mixed TSH/GH adenomas (93, 94), thus emphasizing the importance of systematic measurement of TSH and FT4 in patients with pituitary tumor. Pituitary tumors with positive TSHβ staining removed from patients without clinical and biochemical manifestations of central hyperthyroidism have been recently reported by different groups (9, 64). The secretion from tumoral thyrotrophs of TSH molecules with poor biological activity might represent the explanation for these silent TSH-omas. On the other hand, cardiotoxicosis with atrial fibrillation and/or cardiac failure was reported in sporadic cases (95) and typical episodes of periodic paralysis have also been described in Asiatic patients (20).

The presence of a goiter is the rule, even in the patients with previous partial thyroidectomy, since thyroid residue may regrow as a consequence of TSH hyperstimulation. Occurrence of uni- or multinodular goiter is frequent (about 72% of reported cases), but progression towards functional autonomy seems to be rare (96). The monitoring of the thyroid nodule(s) and the execution of fine needle aspiration biopsy (FNAB) are indicated in TSH-omas since differentiated thyroid carcinomas were documented in several patients (1, 11, 55, 97, 98). The prevalence of circulating antithyroid autoantibodies (anti-thyroglobulin: Tg-Ab, and anti-thyroid peroxidase: TPO-Ab) is similar to that found in the general population, but some patients developed Graves' disease after pituitary surgery and a few others presented bilateral exophthalmos due to autoimmune thyroiditis (1, 55, 99), while unilateral exophthalmos due to orbital invasion by the pituitary tumor was also reported (3, 100).

Dysfunction of the gonadal axis is not rare, with menstrual disorders present in one third of the reported cases, mainly in the mixed TSH/PRL adenomas. Central hypogonadism, delayed puberty and decreased libido were also found in a number of males with TSH-omas and/or mixed TSH/FSH adenomas (1, 90, 101).

As a consequence of tumor suprasellar extension or invasiveness, signs and symptoms of expanding tumor mass are predominant in many patients. Partial or total hypopituitarism was seen in about 1/4 cases, headache reported in 20-25% of patients and visual field defects are present in about 50% of cases (Figure 1).

BIOCHEMICAL FINDINGS

High concentrations of circulating free thyroid hormones in the presence of detectable TSH levels characterize the hyperthyroidism secondary to TSH-secreting pituitary adenomas. Normal levels of total T4 were recorded in several patients with TSH-oma despite the presence of clinical signs and symptoms of hyperthyroidism. This observation indicates that the measurement of circulating free thyroid hormones (FT4 and FT3) is mandatory. In fact, these measurements show the highest sensitivity for the correct diagnosis of central hyperthyroidism and prevent misclassification in the case of excess of circulating levels of thyroxine-binding globulin (26). Many different physiological or clinical conditions, such as pregnancy or RTH, may present with hyperthyroxinemia and detectable serum TSH levels, and should be distinguished from TSH-omas. Most of these conditions may be recognized on the basis of either a patient's clinical history or by measuring the concentrations of FT4 and FT3 with direct "two-step" methods, i.e. the methods able to avoid possible interference due to the contact between serum factors and tracer at the time of the assay (e.g. equilibrium dialysis+RIA, adsorption chromatography+RIA, and back-titration) (102, 103). In fact, some factors may interfere with the measurement of either thyroid hormones or TSH. The presence of anti-iodothyronine autoantibodies (anti-T4 and/or anti-T3) or abnormal albumin/transthyretin forms, such as those circulating in familial dysalbuminemic hyperthyroxinemia, may cause FT4 and/or FT3 to be overestimated, particularly when "one-step" analog methods are employed (104). The more common factors interfering in TSH measurement and giving spuriously high levels of TSH are the circulating heterophilic antibodies, i.e. antibodies directed against mouse gamma-globulins (36, 105).

About 30% of TSH-oma patients and intact thyroid showed TSH levels within the normal range. Furthermore, despite the TSH-dependent origin of hyperthyroidism, there is no direct correlation between free thyroid hormone and immunoreactive TSH levels (Figure 2). An increased biological activity of secreted TSH molecules likely accounts for the finding of normal TSH in the presence of high levels of FT4 and FT3 (93). TSH molecules secreted by pituitary tumors are heterogeneous and may have either normal, reduced, or increased ratio between their biological and immunological activities, probably due to modification of glycosylation processes secondary to alterations of the post-translational processing of the hormone within the tumor cell (106, 107). Interestingly, TSH levels in patients previously treated with thyroid ablation were 6-fold higher than in untreated patients, though free thyroid hormone levels were still in the hyperthyroid range (1). Moreover, tumoral thyrotrophs may undergo more active cellular proliferation in response to even small reduction in circulating thyroid hormone levels, as documented by the higher number of invasive macroadenomas found in previously treated patients (Figure 1), beyond the increase of TSH secretion.

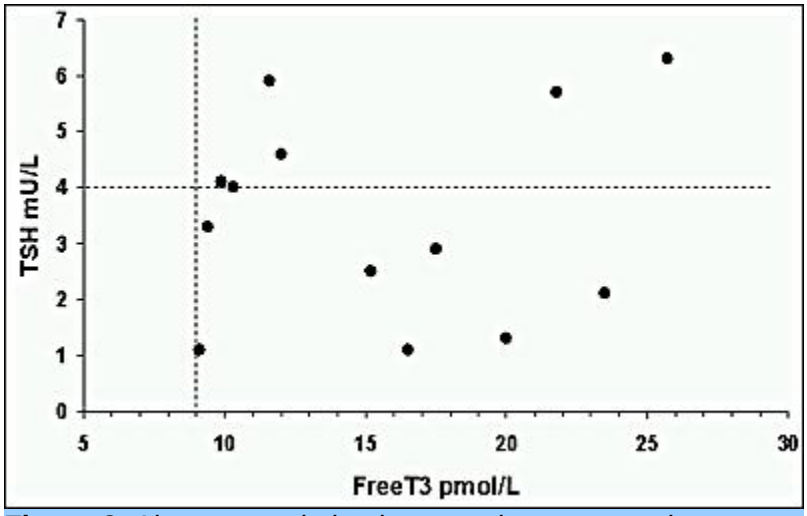

Figure 2. Absent correlation between immunoreactive consentrations of circulating TSH and FT3 in 14 patients with TSH-secreting adenomas. Dotted lines indicate the upper limits of normal ranges for both parameters.

Independently of previous thyroid ablation, circulating free α-GSU levels and α-GSU/TSH molar ratio were clearly elevated in the majority of patients with TSH-oma, either due to unbalanced secretion of the subunit or to the presence of a mixed TSH/α-GSU adenoma (51). The calculation of the α-GSU/TSH molar ratio increases the diagnostic sensitivity of hormone measurement, and a α-GSU/TSH molar ratio above 1.0 was associated with the presence of a TSH-secreting pituitary adenoma (108). However, more recent data show that the individual values must be compared with those of control groups matched for TSH and gonadotropin levels before drawing any diagnostic conclusions. Controls with normal levels of TSH and gonadotropins may have α-GSU/TSH molar ratios as high as 5.7, and values as high as 29.1 can be found in euthyroid postmenopausal women (1, 109). Indeed, hypersecretion of α-GSU is not unique of TSH-omas, being present in the majority of true gonadotropinomas, in a subset of nonfunctioning pituitary adenomas and in a number of GH- or PRL-secreting tumors. Moreover, high α-GSU levels may be observed in conditions other than pituitary adenomas, such as in patients with inflammatory bowel diseases (e.g., ulcerative colitis, Crohn disease), or with other neuroendocrine tumors (e.g., carcinoids) (109).

PARAMETERS OF THYROID HORMONE ACTION

Patients with central hyperthyroidism may present with mild signs and symptoms of thyroid hormone overproduction. Therefore, the measurements of several parameters of peripheral thyroid hormone action have been proposed to quantify the degree of tissue hyperthyroidism (1, 5-8, 94). Some of them are measured *in vivo* (basal metabolic rate, cardiac systolic time intervals, "Achilles" reflex time) and others *in vitro* (sex hormone-binding globulin: SHBG, cholesterol, angiotensin converting enzyme, soluble interleukin-2 receptor, osteocalcin, carboxyterminal cross-linked telopeptide of type I collagen (ICTP), etc.). In particular, liver (SHBG) and bone parameters (ICTP) have been successfully used to differentiate hyperthyroid patients with TSH-oma from those with pituitary resistance to thyroid hormone (PRTH) (Figure 3). In fact, as it occurs in the common forms of hyperthyroidism, patients with TSH-oma have high SHBG and ICTP levels, while they are in the normal range in patients with hyperthyroidism due to PRTH (110, 111).

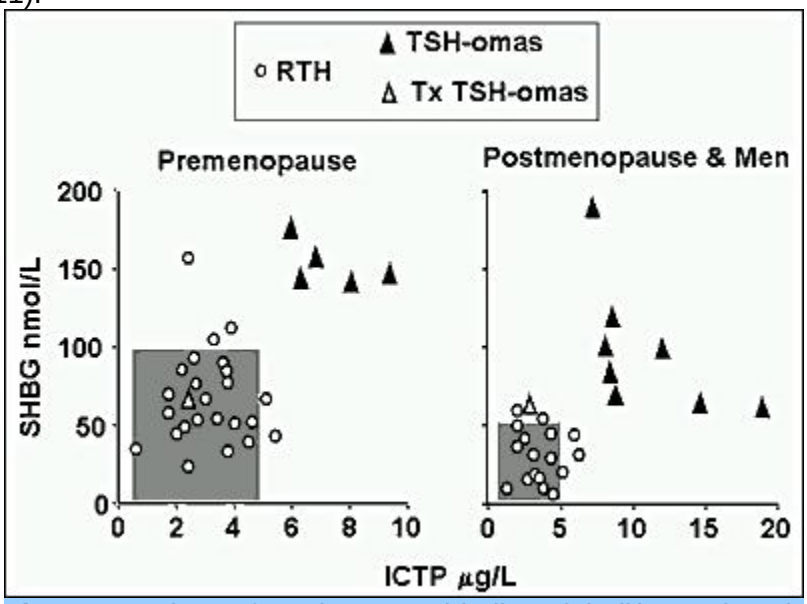

Figure 3. Values of sex hormone-binding globuli(SHBG) and carboxyterminal cross-linked telopeptide of type 1 collagen (ICTP) in patients with RTH or TSH-omas. Shaded areas represent the normal ranges either in premenopause or in postmenopause women and men. The combined measurement of parameters from different tissues may be

useful for the differential diagnosis and by-pass possible interference by different factors (age, liver or bone diseases, combined alteration of pituitary functions, treatments, etc.).

DYNAMIC TESTING

Both stimulatory and inhibitory tests had been proposed for the diagnosis of TSH-oma. Classically, T3 suppression test has been used to assess the presence of a TSH-oma. A complete inhibition of TSH secretion after T3 suppression test (80-100 ug/day for 8-10 days) has never been recorded in patients with TSH-oma. In patients with previous thyroid ablation, T3 suppression seems to be the most sensitive and specific test in assessing the presence of a TSH-oma (2, 8, 94). However this test is strictly contraindicated in elderly patients or in those with coronary heart disease. TRH testing has been widely used to investigate the presence of a TSH-oma. In the vast majority of patients, TSH and α-GSU levels do not increase after TRH injection. In patients with hyperthyroidism, discrepancies between TSH and α-GSU responses to TRH are pathognomonic of TSH-omas cosecreting other pituitary hormones. Such a discrepancy is also found in an opposite clinical condition, i.e. the congenital hypothyroidism due to TSHβ gene mutation (112).

The majority of TSH-omas maintains the sensitivity to native somatostatin and its analogs. Indeed, administration of native neuropeptide or its analogs (octreotide and lanreotide) induces a reduction of TSH levels in the majority of cases and these tests may be predictive of the efficacy of long-term treatment (30, 84-88). Since none of these tests is of clear-cut diagnostic value, we recommend the use of both T3 suppression and TRH test whenever possible, because the combination of their results increases the specificity and sensitivity of the diagnostic work-up.

IMAGING STUDIES AND LOCALIZATION OF THE TUMOR

As for other tumors of the region of the sella turcica, nuclear magnetic resonance imaging (MRI) is nowadays the preferable tool for the visualization of a TSH-oma. High-resolution computed tomography (CT) is the alternative investigation in the case of contraindications, such as patients with pace-maker. Most TSH-omas have been diagnosed at the stage of macroadenomas, and various degrees of suprasellar extension or sphenoidal sinus invasion were seen in two thirds of cases.

Microadenomas are now reported with increasing frequency, accounting for about 15% of all recorded cases in both clinical and surgical series. Recently, pituitary scintigraphy with radiolabeled octreotide (octreoscan) has been shown to successfully localize TSH-omas expressing somatostatin receptors (8, 113). However, the specificity of octreoscan is low, since positive scans can be seen in the case of a pituitary mass of different types, either secreting or non-secreting.

Finally, ectopic localization of TSH-oma has been reported by three groups who found at the CT scan a nasopharyngeal mass in three patients with clinical and biochemical features of central hyperthyroidism (21, 32, 114). Histological and immuno histochemical studies of both specimen collected during the operation showed unequivocally that the tumor was a TSH-oma, and the resection of the mass restored TSH and α-GSU levels to normal.

DIFFERENTIAL DIAGNOSIS

If FT4 and FT3 concentrations are elevated in the presence of measurable TSH levels, it is important to exclude methodological interference, due to the presence of circulating auto-antibodies or heterophilic antibodies. In a patient with signs and symptoms of hyperthyroidism, the confirmed presence of elevated FT4/FT3 and detectable TSH levels rules out Graves' disease or other forms of primary hyperthyroidism. In patients on L-T4 replacement therapy, the finding of measurable TSH in the presence of high FT4/FT3 levels may be due to poor compliance or to an incorrect high L-T4 dosage, probably administered before blood sampling.

When the existence of central hyperthyroidism is confirmed, several diagnostic steps have to be carried out to differentiate a TSH-oma from RTH (Table 2) (1, 5-8, 30, 83, 84). The presence of neurological signs and symptoms (visual defects, headache) of an expanding intra-cranial mass or clinical features of concomitant hypersecretion of other pituitary hormones (acromegaly, galactorrhea/amenorrhea) points to

the presence of a TSH-oma. The presence of alterations of pituitary content at MRI or CT scan strongly supports the diagnosis of TSH-oma. Nevertheless, the differential diagnosis may be difficult when the pituitary adenoma is very small, or in the case of confusing lesions, such as an empty sella. Moreover, the possibility of pituitary incidentalomas should always be considered, due to their high occurrence. In our series, about 20% of RTH patients have a pituitary lesion at MRI.

No significant differences in age, sex, previous thyroid ablation, TSH levels or free thyroid hormone concentrations were seen between patients with TSH-oma and those with RTH. However, in contrast with RTH patients, familial cases of TSH-oma have never been documented. Serum TSH levels within the normal range are more frequently found in RTH, while elevated α-GSU concentrations and/or high α-GSU/TSH molar ratio are typically present in patients with TSH-omas. Moreover, TSH unresponsiveness to TRH stimulation and/or to T3 suppression tests favours the presence of a TSH-oma. Indexes of thyroid hormone action at the tissue level (such as SHBG or ICTP levels) are in the hyperthyroid range in most patients with TSH-oma, while they are generally normal/low in RTH (Figure 3). Exceptions are the findings of normal SHBG levels in patients with mixed GH/TSH adenoma, due to the inhibitory action of GH on SHBG synthesis and secretion, and of high SHBG in RTH patients treated with estrogens or showing profound hypogonadism. Genetic analysis of TRβ gene may be useful in the differential diagnosis, as TRβ mutations in leukocyte DNA have been found only in patients with RTH.

Another parameter that can be useful for the differential diagnosis is the evaluation of the sensitivity to long-acting somatostatin analog (30). More than 90% of TSH-oma are sensitive and 2 or more administrations of analog are usually sufficient to induce significant decreases or normalization of circulating free thyroid hormone. These modifications have never been observed in RTH patients (Table 2).

Table 2. Differential diagnosis between TSH-secreting adenomas (TSH-omas) and resistance to thyroid hormones (RTH). Only patients with intact thyroid were taken into account. Data are obtained from patients followed at our Department and are expressed as mean±SE.

Parameter	**TSH-omas**	**RTH**	**P**
Female/Male ratio	1.3	1.4	NS
Familial cases	0 %	82 %	<0.0001
TSH mU/L	3.0 ±0.4	2.3 ±0.3	NS
FT4 pmol/L	38.8 ±3.9	29.9 ±2.3	NS
FT3 pmol/L	14.0 ±1.2	11.3 ±0.8	NS
Lesions at CT or MRI	99 %	23 %	<0.0001
Germinal TRβ mutation	0%	84%	<0.0001
High TSH B/I	38%	90%	NS
High α-GSU levels	69 %	3 %	<0.0001
High α-GSU/TSH m.r.	81 %	2 %	<0.0001
Elevated SHBG and/or ICTP	90%	8%	<0.0001
Blunted TSH response to TRH test	87 %	2 %	<0.0001
Abnormal TSH response to T3 suppression [a]	100 %	100 % [b]	NS
FT4/FT3 reduction/normalization during long-acting somatostatin analog[c]	92%	0%	<0.0001

[a] Werner's test (80-100 ug T3 for 8-10 days). Quantitatively normal responses to T3, i.e. complete inhibition of both basal and TRH-stimulated TSH levels, have never been recorded in either group of patients.
[b] Although abnormal in quantitative terms, TSH response to T3 suppression test was qualitatively normal in 45/47 RTH patients.
[c] Two or more injections of somatostatin analogs (e.g., Octreotide-LAR 20-30 mg every month or Lanreotide Autogel 120 mg every 6-8 weeks)

TREATMENT AND OUTCOME

Surgical resection is the recommended therapy for TSH-secreting pituitary tumors, with the aim of removing neoplastic tissues and restoring normal pituitary/thyroid function. However, a radical removal of the large tumors, that still represent the majority of TSH-omas, is particularly difficult because of the marked fibrosis of these tumors and the local invasion involving the cavernous sinus, internal carotid artery or optic chiasm. Considering this high invasiveness, surgical removal or debulking of the tumor by transsphenoidal or subfrontal adenomectomy, depending on the tumor volume and its suprasellar extension, should be undertaken as soon as possible. Particular attention has to be paid to presurgical preparation of the patient: antithyroid drugs or octreotide along with propranolol should be used, aiming at restoration of euthyroidism. In patients with very severe hyperthyroidism, the administration of iopanoic acid may be successfully employed (25). After surgery, partial or complete hypopituitarism may result (115). However, a case of thyroid storm after pituitary surgery was recently documented (116). Evaluation of pituitary function, particularly ACTH secretion, should be carefully undertaken soon after

surgery and hormone replacement therapy initiated, if needed. In case of failure of pituitary surgery and in the presence of life-threatening hyperthyroidism, total thyroidectomy or thyroid ablation with radioiodine is indicated (117).

If surgery is contraindicated or declined, as well as in the case of surgical failure, pituitary radiotherapy and/or medical treatment with somatostatin analogs are two valid alternatives. In the case of radiotherapy, the recommended dose is no less than 45 Gy fractionated at 2 Gy per day or 10-25 Gy in a single dose if a stereotactic Gamma Unit is available. A successful experience of an invasive TSH-oma associated with an unruptured aneurysm treated by two-stage operation and gamma knife has been recently reported (118). Although earlier diagnosis has improved the surgical cure rate of TSH-omas, several patients have required medical therapy in order to control the hyperthyroidism. Dopamine agonists, and particularly cabergoline, have been employed in some TSH-omas with variable results, positive effects being mainly observed in some patients with mixed PRL/TSH adenoma (119, 120). Today, the medical treatment of TSH-omas rests on long-acting somatostatin analogs, such as octreotide or lanreotide (12, 13, 85, 121, 122). Treatment with these analogs leads to a reduction of TSH and α-GSU secretion in almost all cases, with restoration of the euthyroid state in the majority of them and it is safe even during pregnancy (18, 24). In some cases, inhibition of tumoral TSH secretion may be so profound that hypothyroidism may even be seen. During somatostatin analog therapy tumor shrinkage occurs in about 50% of patients and vision improvement in 75% (122). Rapid shrinkage of tumor has been recently described (34). Resistance to octreotide treatment has been documented in few cases. Patients on somatostatin analogs have to be carefully monitored, as untoward side effects, such as cholelithiasis and carbohydrate intolerance, may become manifest. The dose administered should be tailored for each patient, depending on therapeutic response. The tolerance is usually very good, as gastrointestinal side effects are transient with long-acting analogs (12, 13, 57, 121, 122).

CRITERIA OF CURE AND FOLLOW-UP

Due to the rarity of the disease and the great heterogeneity of the methods used, the criteria of cure of patients operated or irradiated for TSH-omas has not been clearly established. Previous thyroid ablation makes some of these criteria not applicable (Table 3).

Table 3. Criteria for the evaluation of the outcome of treatment.	
Criteria	Comments
Remission from hyperthyroid manifestations(clinical and biochemical)	Clinical improvement may be transient No predictive value
Disappearance of neurological manifestations(adenoma imaging, visual field defects, headache)	May be transient Poor predictive value
Normalization of free thyroid hormone levels	Biochemical remission may be transient Poor predictive value
Normalization of circulating TSH levels	Not applicable to patients with normal TSH Poor predictive value
Undetectable TSH one week after neurosurgery	Applicable to hyperthyroid patients that stopped treatments at least 10 days before surgery Good prognostic value
Normalization of α-GSU levels and α-GSU/TSH m.r.	Not applicable to patients with normal values before neurosurgery Lack of sensitivity
Positive T3-suppression test with undetectable TSH and no response to TRH (or central hypothyroidism)	Optimal sensitivity/specificity and predictive value Test is contraindicated in elderly patients or in those with cardiac diseases

In untreated hyperthyroid patients, it is reasonable to assume that cured patients have clinical and biochemical reversal of thyroid hyperfunction. However, the findings of normal free thyroid hormone concentrations or indices of peripheral thyroid hormone action (SHBG, ICTP, etc.) are not synonymous with complete removal or destruction of tumoral cells, since transient clinical remission accompanied by normalization of thyroid function is possible (94). Disappearance of neurological signs and symptoms is a good prognostic event, but lacks both sensitivity and specificity, as even an incomplete debulking of the tumor may cause visual field defects and headache to vanish. The resolution of specific neuroradiological abnormalities is confusing, since the pituitary imaging performed soon after surgery is often difficult to interpret. The criteria of normalization of circulating TSH is not applicable to previously thyroidectomized patients and to the 26% of patients with normal basal values of TSH. In our experience, undetectable TSH levels one week after surgery are likely to indicate complete adenomectomy, provided that the patient was hyperthyroid and presurgical treatments were stopped before surgery (94).
Normalization of α-GSU and/or α-GSU/TSH molar ratio is in general a good index for the evaluation of therapy efficacy (8, 94). However, both parameters are characterized by less than optimal sensitivity, as they are normal in about 25% of patients with TSH-oma. The most sensitive and specific test to document the complete removal of the adenoma remains, in the absence of contraindication, the T3 suppression test (94). In fact, only patients in whom T3 administration completely inhibits basal and TRH-stimulated TSH secretion, appear to be truly cured.
No data on the recurrence rates of TSH-oma in patients judged cured after surgery or radiotherapy have been reported. However, the recurrence of the adenoma does not appear to be frequent, at least in the first years after successful surgery (94). In general, the patient should be evaluated clinically and biochemically 2 or 3 times the first year postoperatively, and then every year. Pituitary imaging should be performed every two or three years, but should be promptly done whenever an increase in TSH and

thyroid hormone levels, or clinical symptoms occur. In the case of persistent macroadenoma, a close visual field follow-up is required, as the visual function is threatened. Emergency surgical decompression is not always able to reverse even a recent visual deficit.

REFERENCES

1. Beck-Peccoz P, Brucker-Davis F, Persani L, Smallridge RC, Weintraub BD. Thyrotropin-secreting pituitary tumors. Endocr Rev 1996; 17:610-638
2. Beck-Peccoz P, Persani L. Chapter 24. TSH-producing adenomas. In: JL Jameson, LJ DeGroot, (Eds) "Endocrinology. 5th edition", W.B. Saunders Pub., USA, 2010, pp.324-332
3. Jailer JW, Holub DA. Remission of Graves' disease following radiotherapy of a pituitary neoplasm. Am J Med 1960; 28:497-500,
4. Hamilton C, Adams LC, Maloof F Hyperthyroidism due to thyrotropin-producing pituitary chromophobe adenoma. N Engl J Med 1970; 283:1077-1080
5. Refetoff S, Weiss RE, Usala SJ: The syndromes of resistance to thyroid hormone. Endocr Rev 1993; 14:348-399
6. Refetoff S., Dumitrescu AM. 2010 Resistance to thyroid hormone, in Thyroid Disease Manager, Chapter 16D (http://www.thyroidmanager.org)
7. Gurnell M, Visser TJ, Beck-Peccoz P, Chatterjee VKK. 2010 Resistance to Thyroid Hormone: in Endocrinology, Adult and Pediatric (6th Edition, vol. II), edited by Jameson LJ and DeGroot LJ. Sauderns Elsevier, Philadelphia, PA, pp. 1745-1759.
8. Brucker-Davis F, Oldfield EH, Skarulis MC, Doppman JL, Weintraub BD: Thyrotropin-secreting pituitary tumors: diagnostic criteria, thyroid hormone sensitivity, and treatment outcome in 25 patients followed at the National Institutes of Health. J Clin Endocrinol Metab 1999; 84: 476-486
9. Bertholon-Grégoire M, Trouillas J, Guigard MP, Loras B, Tourniaire J: Mono- and plurihormonal thyrotropic pituitary adenomas: pathological, hormonal and clinical studies in 12 patients. Eur J Endocrinol 1999; 140: 519-527
10. Taylor TJ, Donlon SS, Bale AE, Smallridge RC, Francis TB, Christensen RS, Burma KD. Treatment of a thyrotropinoma with octreotide-LAR in a patient with multiple endocrine neoplasia-1. Thyroid 2000; 10: 1001-1007
11. Kishida M, Otsuka F, Kataoka H, Yokota K, Oishi T, Yamauchi T, Doihara H, Tamiya T, Mimura Y, Ogura T, Makino H. Hyperthyroidism in a patient with TSH-producing pituitary adenoma coexisting with thyroid papillary adenocarcinoma. Endocr J 2000; 47:731-738
12. Kuhn JM, Arlot S, Lefebvre H; Caron P, Cortet-Rudelli C, Archambaud F, Chanson P, Tabarin A, Goth MI, Blumberg J, Catus F, Ispas S, Beck-Peccoz P: Evaluation of the treatment of thyrotropin-secreting pituitary adenomas with a slow release formulation of the somatostatin analog lanreotide. J Clin Endocrinol Metab 2000; 85:1487-1491
13. Caron P, Arlot S, Bauters C, Chanson P, Kuhn JM, Pugeat M, Marechaud R, Teutsch C, Vidal E, Sassano P. Efficacy of the long-acting octreotide formulation (octreotide-LAR) in patients with thyrotropin-secreting pituitary adenomas. J Clin Endocrinol Metab 2001; 86:2849-2853
14. Sunthornthepvarakul T, Prachasilchai P, Komindr A, Ngowngarmaratana S, Dansirikul R. A case of thyrotropin-secreting pituitary macroadenoma. J Med Assoc Thai 2001; 84:897-906
15. Kon YC, Loh KC, Tambyah JA, Lim LH, Marshall JC. Thyrotropin (TSH)-secreting pituitary macroadenoma with cavernous sinus invasion. Singapore Med J 2001; 42:433-439.
16. Garcia Lafuente N, Berna Gascon MT, Pujalte Lopez E, Falco Jover G, Dominguez Escribano JR. Response of thyrotropinoma to somatostatin analogues: report of a case. Ann Med Interna 2001; 18:663
17. Tella OI jr, Herculano MA, Delcello R, Prandini MN. TSH pituitary adenoma: case report. Arq Neuropsiquiatr 2002; 60:129-132
18. Blackhurst G, Strachan MW, Collie D, Gregor A, Statham PF, Seckl JE. The treatment of a thyrotropin-secreting pituitary macroadenoma with octreotide in twin pregnancy.Clin Endocrinol (Oxf). 2002;57:401-404.
19. Kuo CS, Ho DM, Yang AH, Lin HD. Thyrotropin-secreting pituitary adenoma with growth hormone hypersecretion. Zhonghua Yi Xue Za Zhi (Taipei). 2002;65:489-943.

20. Hsu FS, Tsai WS, Chau T, Chen HH, Chen YC, Lin SH. Thyrotropin-secreting pituitary adenoma presenting as hypokalemic periodic paralysis. Am J Med Sci. 2003;325:48-50.
21. Pasquini E, Faustini-Fustini M, Sciarretta V, Saggese D, Roncaroli F, Serra D, Frank G. Ectopic TSH-secreting pituitary adenoma of the vomerosphenoidal junction.Eur J Endocrinol. 2003;148:253-257.
22. Socin HV, Chanson P, Delemer B, Tabarin A, Rohmer V, Mockel J, Stevenaert A, Beckers A. The changing spectrum of TSH-secreting pituitary adenomas: diagnosis and management in 43 patients. Eur J Endocrinol. 2003;148:433-442.
23. Wu YY, Chang HY, Lin JD, Chen KW, Huang YY, Jung SM. Clinical characteristics of patients with thyrotropin-secreting pituitary adenoma. J Formos Med Assoc. 2003;102:164-171.
24. Chaiamnuay S, Moster M, Katz MR, Kim YN. Successful management of a pregnant woman with a TSH secreting pituitary adenoma with surgical and medical therapy. Pituitary. 2003;6:109-113.
25. Dhillon KS, Cohan P, Kelly DF, Darwin CH, Iyer KV, Chopra IJ. Treatment of hyperthyroidism associated with thyrotropin-secreting pituitary adenomas with iopanoic acid. J Clin Endocrinol Metab. 2004;89:708-711.
26. Soubhi Nizam M, Kennedy L. Co-occurrence of thyroid binding globulin excess and a pituitary macroadenoma containing thyroid stimulating hormone-producing cells.
Postgrad Med J. 2004;80:114-115.
27. Hubalewska-Hola A, Fross K, Kostecka-Matyja M, Sowa-Staszczak A, Szybinski Z, Huszno B, Ptak M. Macro- and microadenoma of thyrotropin secreting pituitary tumors--two clinical cases.
Przegl Lek. 2003; 60:768-171.
28. Teramoto A, Sanno N, Tahara S, Osamura YR. Pathological study of thyrotropin-secreting pituitary adenoma: plurihormonality and medical treatment. Acta Neuropathol (Berl). 2004;108:147-153.
29. Yang D, Tao W, Liu TH, Wei SZ. [Thyrotropin-secreting pituitary adenoma:a clinicopathological analysis of seven cases] Zhonghua Bing Li Xue Za Zhi. 2004 Jun;33(3):208-11.
30. Mannavola D, Persani L, Vannucchi G, et al. Different response to chronic somatostatin analogues in patients with central hyperthyroidism. Clin Endocrinol (Oxf) 2005; 62: 176–181
31. Del Monte P, Bernasconi D, Ruelle A, Marugo A, Marugo M, Torre R. Effect of long-term treatment with octreotide-lar in a TSH-secreting pituitary macroadenoma and secondary hyperthyroidism. Minerva Endocrinol. 2005 Jun;30(2):95-9.
32. Collie RB, Collie MJ. Extracranial thyroid-stimulating hormone-secreting ectopic pituitary adenoma of the nasopharynx. Otolaryngol Head Neck Surg. 2005 Sep;133(3):453-4.
33. Usui T, Izawa S, Sano T, Tagami T, Nagata D, Shimatsu A, Takahashi JA, Naruse M. Clinical and molecular features of a TSH-secreting pituitary microadenoma. Pituitary. 2005;8(2):127-34.
34. Atkinson JL, Abboud CF, Lane JI. Dramatic volume reduction of a large GH/TSH secreting pituitary tumor with short term Octreotide therapy. Pituitary. 2005;8(2):89-91.
35. Brown RL, Muzzafar T, Wollman R, Weiss RE. A pituitary carcinoma secreting TSH and prolactin: a non-secreting adenoma gone awry. Eur J Endocrinol. 2006 May;154(5):639-43.
36. Tan MJ, Tan F, Hawkins R, Cheah WK, Mukherjee JJ. A hyperthyroid patient with measurable thyroid-stimulating hormone concentration - a trap for the unwary. Ann Acad Med Singapore. 2006 Jul;35(7):500-3.
37. Meas T, Sobngwi E, Vexiau P, Boudou P. An unusual somatotropin and thyreotropin secreting pituitary adenoma efficiently controlled by Octreotide and Pegvisomant. Ann Endocrinol (Paris). 2006 Jun;67(3):249-52.
38. Gołkowski F, Buziak-Bereza M, Stefańska A, Trofimiuk M, Pantofliński J, Huszno B, Czepko R, Adamek D. [A case of GH and TSH secreting pituitary macroadenoma] Przegl Lek. 2006;63(2):106-8.
39. Losa M, Mortini P, Minelli R, Giovanelli M. Coexistence of TSH-secreting pituitary adenoma and autoimmune hypothyroidism. J Endocrinol Invest. 2006 Jun;29(6):555-9.
40. Kienitz T, Quinkler M, Strasburger CJ, Ventz M. Long-term management in five cases of TSH-secreting pituitary adenomas: a single center study and review of the literature. Eur J Endocrinol. 2007 Jul;157(1):39-46.
41. Foppiani L, Del Monte P, Ruelle A, Bandelloni R, Quilici P, Bernasconi D. TSH-secreting adenomas: rare pituitary tumors with multifaceted clinical and biological features. J Endocrinol Invest. 2007 Jul-Aug;30(7):603-9.
42. Ness-Abramof R, Ishay A, Harel G, Sylvetzky N, Baron E, Greenman Y, Shimon I.

TSH-secreting pituitary adenomas: follow-up of 11 cases and review of the literature. Pituitary. 2007;10(3):307-10.
43. Ogawa Y, Tominaga T, Ikeda H. [Intrasellar small TSH secreting pituitary adenomas, 2 case reports]. No Shinkei Geka. 2007 Jul;35(7):679-84.
44. Losa M, Fortunato M, Molteni L, Peretti E, Mortini P. Thyrotropin-secreting pituitary adenomas: biological and molecular features, diagnosis and therapy. Minerva Endocrinol. 2008 Dec;33(4):329-40..
45. Clarke MJ, Erickson D, Castro MR, Atkinson JL. Thyroid-stimulating hormone pituitary adenomas. J Neurosurg. 2008 Jul;109(1):17-22..
46. Caron P. [Thyrotropin-secreting pituitary adenomas]. Presse Med. 2009 Jan;38(1):107-11..
47. Macchia E, Gasperi M, Lombardi M, Morselli L, Pinchera A, Acerbi G, Rossi G, Martino E. Clinical aspects and therapeutic outcome in thyrotropin-secretingpituitary adenomas: a single center experience. J Endocrinol Invest. 2009 ;32(9):773-9
48. Duarte FH, Jallad RS, Salgado LR, Bronstein MD. TSH-secreting pituitary tumors: two case reports and literature review. Arq Bras Endocrinol Metabol. 2009 Dec;53(9):1157-66..
49. Elston MS, Conaglen JV. Clinical and biochemical characteristics of patients with TSH-secreting pituitary adenomas from one New Zealand centre. Intern Med J. 2009; 40(3):214-9.
50. Marucci G, Faustini-Fustini M, Righi A, Pasquini E, Frank G, Agati R, Foschini MP. Thyrotropin-secreting pituitary tumours: significance of "atypical adenomas" in a series of 10 patients and association with Hashimoto thyroiditis as a cause of delay in diagnosis. J Clin Pathol. 2009 May;62(5):455-9.
51.Latrech H, Rousseau A, Le Marois E, Billaud L, Bertagna X, Azzoug S, Raffin-Sanson ML. Manifestations and prognosis of thyrotropin-secreting pituitary adenomas: a case series of three patients. Rev Med Interne. 2010 Dec;31(12):858-62.
52. Daly AF, Tichomirowa MA, Petrossians P, et al. Clinical characteristics and therapeutic responses in patients with germ-line AIP mutations and pituitary adenomas: an international collaborative study. J Clin Endocrinol Metab. 2010 Nov;95(11):E373-83.
53. Raappana A, Koivukangas J, Ebeling T, Pirilä T. Incidence of pituitary adenomas in Northern Finland in 1992-2007. J Clin Endocrinol Metab. 2010 Sep;95(9):4268-75.
54. Lee MT, Wang CY. Concomitant Graves hyperthyroidism with thyrotrophin-secreting pituitary adenoma. South Med J. 2010 Apr;103(4):347-9.
55. Nguyen HD, Galitz MS, Mai VQ, Clyde PW, Glister BC, Shakir MK. Management of coexisting thyrotropin/growth-hormone-secreting pituitary adenoma and papillary thyroid carcinoma: a therapeutic challenge. Thyroid. 2010 Jan;20(1):99-103.
56. Tagami T, Usui T, Shimatsu A, Beniko M, Yamamoto H, Moriyama K, Naruse M. Aberrant expression of thyroid hormone receptor beta isoform may cause inappropriate secretion of TSH in a TSH-secreting pituitary adenoma. J Clin Endocrinol Metab. 2011 Jun;96(6):E948-52.
57. Gatto F, Barbieri F, Gatti M, Wurth R, Schulz S, Ravetti JL, Zona G, Culler MD, Saveanu A, Giusti M, Minuto F, Hofland LJ, Ferone D, Florio T. Balance between somatostatin and D2 receptor expression drives TSH-secreting adenoma response to somatostatin analogues and dopastatins. Clin Endocrinol (Oxf). 2012 Mar;76(3):407-14. 58. Nakayama Y, Jinguji S, Kumakura S, Nagasaki K, Natsumeda M, Yoneoka Y, Saito T, Fujii Y. Thyroid-stimulating hormone (thyrotropin)-secretion pituitary adenoma in an 8-year-old boy: case report. Pituitary. 2012 Mar;15(1):110-5.
59. Rabbiosi S, Peroni E, Tronconi GM, Chiumello G, Losa M, Weber G. Asymptomatic thyrotropin-secreting pituitary macroadenoma in a 13-year-old girl: successful first-line treatment with somatostatin analogs. Thyroid. 2012 Oct;22(10):1076-9.

60. Lee W, Cheung AS, Freilich R. TSH-secreting pituitary carcinoma with intrathecal drop metastases. Clin Endocrinol (Oxf). 2012 Apr;76(4):604-6
61. Önnestam L, Berinder K, Burman P, Dahlqvist P, Engström BE, Wahlberg J., Filipsson Nyström H. National incidence and prevalence of TSH-secreting pituitary adenomas in Sweden. J Clin Endocrinol Metab 2013; in press.
62. Sanno N, Teramoto A, Osamura RY. Thyrotropin-secreting pituitary adenomas. Clinical and biological heterogeneity and current treatment. J Neurooncol 2001; 54: 179-186.
63. Terzolo M, Orlandi F, Bassetti M, Medri G, Paccotti P, Cortelazzi D, Angeli A, Beck-Peccoz P. Hyperthyroidism due to a pituitary adenoma composed of two different cell types, one secreting alpha-subunit alone and another cosecreting alpha-subunit and thyrotropin. J Clin Endocrinol Metab 1991; 72:415-421
64. Banerjee AK, Sharma BS, Kak VK. Clinically and biochemically silent thyrotroph adenoma with oncocytic change. Neurol India 2000; 48:374-377
65. Lim EM, Bhagat CI, Walsh J. Asymptomatic thyrotropin-secreting pituitary microadenoma. Intern Med J 2001; 31:428-429.
66. Iskandar SB, Supit E, Jordan RM, Peiris AN. Thyrotropin-secreting pituitary tumor and Hashimoto's disease: a novel association.South Med J. 2003 ;96:933-936.
67. Ma W, Ikeda H, Watabe N, Kanno M, Yoshimoto T. A plurihormonal TSH-producing pituitary tumor of monoclonal origin in a patient with hypothyroidism. Horm Res. 2003;59:257-261.
68. Ando S, Sarlis NJ, Krishnan J, Feng X, Refetoff S, Zhang MQ, Oldfield EH, Yen PM. Aberrant alternative splicing of thyroid hormone receptor in a TSH-secreting pituitary tumor is a mechanism for hormone resistance. Mol Endocrinol. 2001;15:1529-1538.
69. Ando S, Sarlis NJ, Oldfield EH, Yen PM. Somatic mutation of TRbeta can cause a defect in negative regulation of TSH in a TSH-secreting pituitary tumor. J Clin Endocrinol Metab. 2001;86:5572-5576.
70. Tannahill LA, Visser TJ, McCabe CJ, Kachilele S, Boelaert K, Sheppard MC, Franklyn JA, Gittoes NJ. Dysregulation of iodothyronine deiodinase enzyme expression and function in human pituitary tumours. Clin Endocrinol (Oxf). 2002;56:735-743.
71. Baur A, Buchfelder M, Kohrle J. Expression of 5'-deiodinase enzymes in normal pituitaries and in various human pituitary adenomas. Eur J Endocrinol. 2002;147:263-268.
72. Webster J, Peters JR, John R, Smith J, Chan V, Hall R, Scanlon MF. Pituitary stone: two cases of densely calcified thyrotropin-secreting pituitary adenomas. Clin Endocrinol (Oxf) 1994; 40:137-43
73. Ezzat S, Horvath E, Kovacs K, Smyth HS, Singer W, Asa SL Basic fibroblast growth factor expression by two prolactin and thyrotropin-producing pituitary adenomas. Endocr Pathol 1995; 6:125-134
74. Trouillas J, Girod C, Loras B, Claustrat B, Sassolas G, Perrin G, Buonaguidi R The TSH secretion in the human pituitary adenomas. Pathol Res Pract 1988; 183:596-600
75. Mixson AJ, Friedman TC, David AK, Feuerstein IM, Taubenberger JK, Colandrea JM, Doppman JL, Oldfield EH, Weintraub BD: Thyrotropin-secreting pituitary carcinoma. J Clin Endocrinol Metab 1993; 76:529-533
76. Lu C, Willingham MC, Furuya F, Cheng SY. Activation of phosphatidylinositol 3-kinase signaling promotes aberrant pituitary growth in a mouse model of thyroid-stimulating hormone-secreting pituitary tumors. Endocrinology. 2008;149:3339-45.

77. Dong Q, Brucker-Davis F, Weintraub BD, Smallridge RC, Carr FE, Battey J, Spiegel AM, Shenker A. Screening of candidate oncogenes in human thyrotroph tumors: absence of activating mutations of the G?q, G?11, G?s, or thyrotropin-releasing hormone receptor genes. J Clin Endocrinol Metab 1996; 81:1134-1140
78. Friedman E, Adams EF, Höög A, Gejman PV, Carson E, Larsson C, De Marco L, Werner S, Fahlbusch R, Nordenskjöld M. Normal structural dopamine type 2 receptor gene in prolactin-secreting and other pituitary tumors. J Clin Endocrinol Metab 1994; 78: 568-574
79. Asteria C, Anagni M, Persani L, Beck-Peccoz P. Loss of heterozigosity of the MEN1 gene in a large series of TSH-secreting pituitary adenomas. J Endocrinol Invest 2001; 24:796-801
80. Filopanti M, Ballare E, Lania AG et al. Loss of heterozygosity at the SS receptor type 5 locus in human GH- and TSH-secreting pituitary adenomas. J Endocrinol Invest. 2004;27:937-942.

81. Barlier A, Vanbellinghen JF, Daly AF, Silvy M, Jaffrain-Rea ML, Trouillas J, Tamagno G, Cazabat L, Bours V, Brue T, Enjalbert A, Beckers A. Mutations in the aryl hydrocarbon receptor interacting protein gene are not highly prevalent among subjects with sporadic pituitary adenomas. J Clin Endocrinol Metab. 2007 May;92(5):1952-5.
82. Watanabe K, Kameya T, Yamauchi A, Yamamoto N, Kuwayama A, Takei I, Maruyama H, Saruta T. Thyrotropin-producing adenoma associated with pituitary resistance to thyroid hormone. J Clin Endocrinol Metab 1993; 76:1025-1030
83. Safer JD, Colan SD, Fraser LM, Wondisford FE. A pituitary tumor in a patient with thyroid hormone resistance: a diagnostic dilemma. Thyroid 2001; 11:281-291.
84. Beck-Peccoz P, Persani L. TSH-induced hyperthyroidism caused by a pituitary tumor. Nat Clin Pract Endocrinol Metab. 2006 Sep;2(9):524-8
85. Gancel A, Vuillermet P, Legrand A, Catus F, Thomas F, Kuhn J M. Effets of a slow-release formulation of the new somatostatin analogue lanreotide in TSH-secreting pituitary adenomas. Clin Endocrinol (Oxf) 1994; 40:421-428
86. Bertherat J, Brue T, Enjalbert A, Gunz G, Rasolonjanahary R, Warnet A, Jaquet P, Epelbaum J. Somatostatin receptors on thyrotropin-secreting pituitary adenomas: comparison with the inhibitory effects of octreotide upon in vivo and in vitro hormonal secretions. J Clin Endocrinol Metab 1992; 75:540-546.
87. Yoshihara A, Isozaki O, Hizuka N, Nozoe Y, Harada C, Ono M, Kawamata T, Kubo O, Hori T, Takano K. Expression of type 5 somatostatin receptor in TSH-secreting pituitary adenomas: a possible marker for predicting long-term response to octreotide therapy. Endocr J. 2007 Feb;54(1):133-8.
88. Horiguchi K, Yamada M, Umezawa R, Satoh T, Hashimoto K, Tosaka M, Yamada S, Mori M. Somatostatin receptor subtypes mRNA in TSH-secreting pituitary adenomas: a case showing a dramatic reduction in tumor size during short octreotide treatment. Endocr J. 2007 Jun;54(3):371-8.
89. Wood DF, Johnston JM, Johnston DG. Dopamine, the dopamine D2 receptor and pituitary tumours. Clin Endocrinol (Oxf) 1991; 35:455-466
90. Gesundheit N, Petrick P, Nissim M, Dahlberg PA, Doppman L, Emerson CH, Braverman LE, Oldfield EH, Weintraub BD. Thyrotropin-secreting pituitary adenomas: clinical and biochemical heterogeneity. Ann Intern Med 1989; 111:827-835.
91. Spada A, Bassetti M, Martino E, Giannattasio G, Beck-Peccoz P, Sartorio P, Vallar L, Baschieri L, Pinchera A, Faglia G. In vitro studies on TSH secretion and adenylate cyclase activity in a human TSH-secreting pituitary adenoma. Effects of somatostatin and dopamine. J Endocrinol Invest 1985; 8:193-198
92. Rocheville M, Lange DC, Kumar U, Patel SC, Patel RC, Patel YC. Receptors for dopamine and somatostatin: formation of hetero-oligomers with enhanced functional activity. Science 2000; 288:154-157.
93. Beck-Peccoz P, Piscitelli G, Amr S, Ballabio M, Bassetti M, Giannattasio G, Spada A, Nissim M, Weintraub BD, Faglia G. Endocrine, biochemical, and morphological studies of a pituitary adenoma secreting growth hormone, thyrotropin (TSH), and α-subunit: evidence for secretion of TSH with increased bioactivity. J Clin Endocrinol Metab 1986; 62:704-711
94. Losa M, Giovanelli M, Persani L, Mortini P, Faglia G, Beck-Peccoz P. Criteria of cure and follow-up of central hyperthyroidism due to thyrotropin-secreting pituitary adenomas. J Clin Endocrinol Metab 1996; 81:3086-3090
95. George JT, Thow JC, Matthews B, Pye MP, Jayagopal V. Atrial fibrillation associated with a thyroid stimulating hormone-secreting adenoma of the pituitary gland leading to a presentation of acute cardiac decompensation: a case report. J Med Case Reports. 2008 Feb 28;2:67
96. Abs R, Stevenaert A, Beckers A. Autonomously functioning thyroid nodules in a patient with a thyrotropin-secreting pituitary adenoma: possible cause-effect relationship. Eur J Endocrinol 1994; 131:355-358
97. Gasparoni P, Rubello D, Persani L, Beck-Peccoz P: Unusual association between a thyrotropin-secreting pituitary adenoma and a papillary thyroid carcinoma. Thyroid 1998; 8: 181-183

98. Poggi M, Monti S, Pascucci C, Toscano V. A rare case of follicular thyroid carcinoma in a patient with thyrotropin-secreting pituitary adenoma. Am J Med Sci. 2009 Jun;337(6):462-5.
99. Azukizawa M, Morimoto S, Miyai K, Miki T, Yabu Y, Amino N, Kuma K, Kumahara Y. TSH-producing pituitary adenoma associated with Graves' disease. In: Stockigt JR, Nagataki S (eds) Thyroid Research, vol.VIII, Australian Academy of Sciences, Canberra, 1980: 645-648
100. Yovos JG, Falko JM, O'Dorisio TM, Malarkey WN, Cataland S, Capen CC Thyrotoxicosis and a thyrotropin-secreting pituitary tumor causing unilateral exophthalmos. J Clin Endocrinol Metab 1981; 53:338-343
101. Sy ARG, Bernstein R, Chynn KI, Kourides IA. Reduction in size of a thyrotropin- and gonadotropin-secreting pituitary adenoma treated with octreotide acetate (somatostatin analogue). J Clin Endocrinol Metab 1992; 74:690-694
102. Ekins R. Measurement of free hormones in blood. Endocr Rev 1990; 11:5-4
103. Beck-Peccoz P, Piscitelli G, Cattaneo MG, Faglia G, White EL, Barlow JW, Stockigt JR. Evaluation of free thyroxine methods in the presence of iodothyronine binding autoantibodies. J Clin Endocrinol Metab 1984; 58:736-739
104. Gurnell M, Halsall DJ, Chatterjee VK. What should be done when thyroid function tests do not make sense? Clin Endocrinol (Oxf.) 2011;74:673-678.
105. Zweig MH, Csako G, Spero M. Escape from blockade of interfering heterophile antibodies in a two-site immunoradiometric assay for thyrotropin. Clin Chem 1988; 34:2589-2591.
106. Beck-Peccoz P, Persani L. Variable biological activity of thyroid-stimulating hormone. Eur J Endocrinol 1994; 131:331-340
107. Magner JA, Klibanski A, Fein H, et al.: Ricin and lentil lectin affinity chromatography reveals oligosaccharide heterogeneity of thyrotropin secreted by 12 human pituitary tumors. Metabolism 1992; 41:1009-1015
108. Weintraub BD, Gershengorn MC, Kourides IA, Fein H. Inappropriate secretion of thyroid-stimulating hormone. Ann Intern Med 1981; 95:339-351.
109. Beck-Peccoz P, Persani L, Faglia G. Glycoprotein hormone a-subunit in pituitary adenomas. Trends Endocrinol Metab 1992; 3:41-45.
110. Beck-Peccoz P, Roncoroni R, Mariotti S, Medri G, Marcocci C, Brabant G, Forloni F, Pinchera A, Faglia G Sex hormone-binding globulin measurement in patients with inappropriate secretion of thyrotropin (IST): evidence against selective pituitary thyroid hormone resistance in nonneoplastic IST. J Clin Endocrinol Metab 1990; 71: 19-25
111. Persani L, Preziati D, Matthews CH, Sartorio A, Chatterjee VK, Beck-Peccoz P: Serum levels of carboxyterminal cross-linked telopeptide of type I collagen (ICTP) in the differential diagnosis of the syndromes of inappropriate secretion of TSH. Clin Endocrinol (Oxf.) 1997; 47: 207-214
112. Bonomi M, Proverbio MC, Weber G, Chiumello G, Beck-Peccoz P, Persani L. Hyperplastic pituitary gland, high serum glycoprotein hormone alpha-subunit, and variable circulating thyrotropin (TSH) levels as hallmark of central hypothyroidism due to mutations of the TSH beta gene. J Clin Endocrinol Metab. 2001; 86:1600-1604
113. Losa M, Magnani P, Mortini P, Persani L, Acerno S, Giugni E, Fazio F, Beck-Peccoz P, Giovanelli M. Indium-111 pentetreotide single-photon emission tomography in patients with TSH-secreting pituitary adenomas: correlation with the effect of a single administration of octreotide on serum TSH levels. Eur J Nucl Med 1997; 24: 728-731
114. Cooper DS, Wenig BM. Hyperthyroidism caused by an ectopic TSH-secreting pituitary tumor. Thyroid 1996; 6: 337-343
115. Barzaghi LR, Losa M, Giovanelli M, Mortini P. Complications of transsphenoidal surgery in patients with pituitary adenoma: experience at a single centre. Acta Neurochir (Wien). 2007;149(9):877-85; discussion 885-6.
116. Page KA, Roehmholdt BF, Jablonski M, Mayerson AB. Development of thyroid storm after surgical resection of a thyrotropin-secreting pituitary adenoma. Endocr Pract. 200;14:732-7.
117. Daousi C, Foy PM, MacFarlane IA. Ablative thyroid treatment for thyrotoxicosis due to thyrotropin-producing pituitary tumours. J Neurol Neurosurg

Psychiatry. 2007 Jan;78(1):93-5.
118. Ohki M, Sato K, Tuchiya D, Sato S, Saito S, Kinjo T, Kayama T, Yokura H, Yoshimoto T. A case of TSH-secreting pituitary adenoma associated with an unruptured aneurysm: successful treatment by two-stage operation and gamma knife. No To Shinkei 1999; 51: 895-899
119. Kerstens MN, Kappelle JW, van der Berg G. Partial remission with cabergoline pf a thyrotropin producing pituitary tumor cosecreting prolactin. Proceedings of the 84th Annual Meeting of the Endocrine Society, San Francisco, CA, 2002, Abs # P2-570
120. Mouton F, Faivre-Defrance F, Cortet-Rudelli C, Assaker R, Soto-Ares G, Defoort-Dhellemmes S, Blond S, Wemeau JL, Vantyghem MC. TSH-secreting adenoma improved with cabergoline. Ann Endocrinol (Paris). 2008;69:244-8.
121. Chanson P, Weintraub BD, Harris AG: Octreotide therapy for thyroid stimulating-secreting pituitary adenomas. A follow-up of 52 patients. Ann Intern Med 1993; 119:236-240
122. Beck-Peccoz P, Persani L. Medical management of thyrotropin-secreting pituitary adenomas. Pituitary 2002;5:83-8.